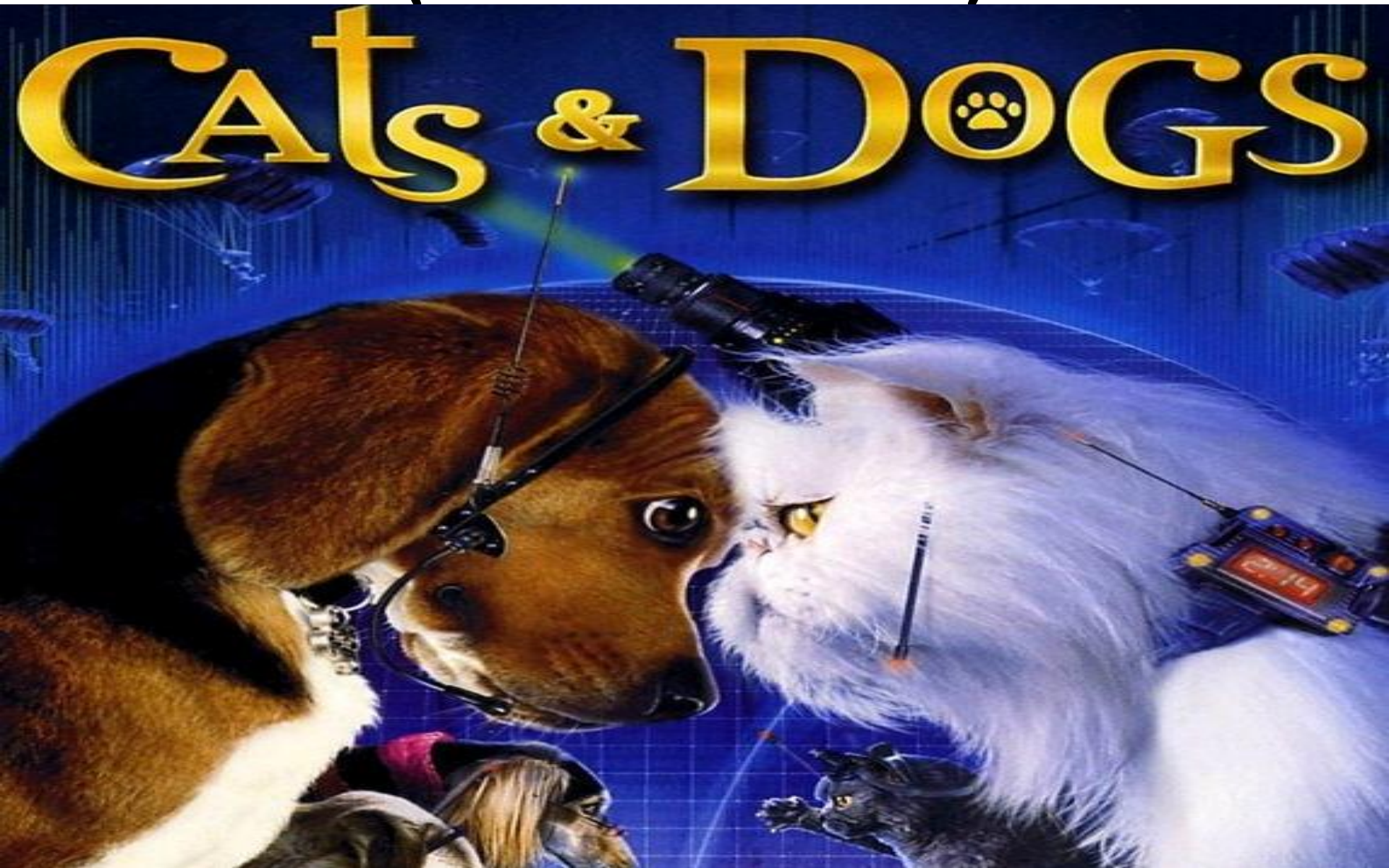
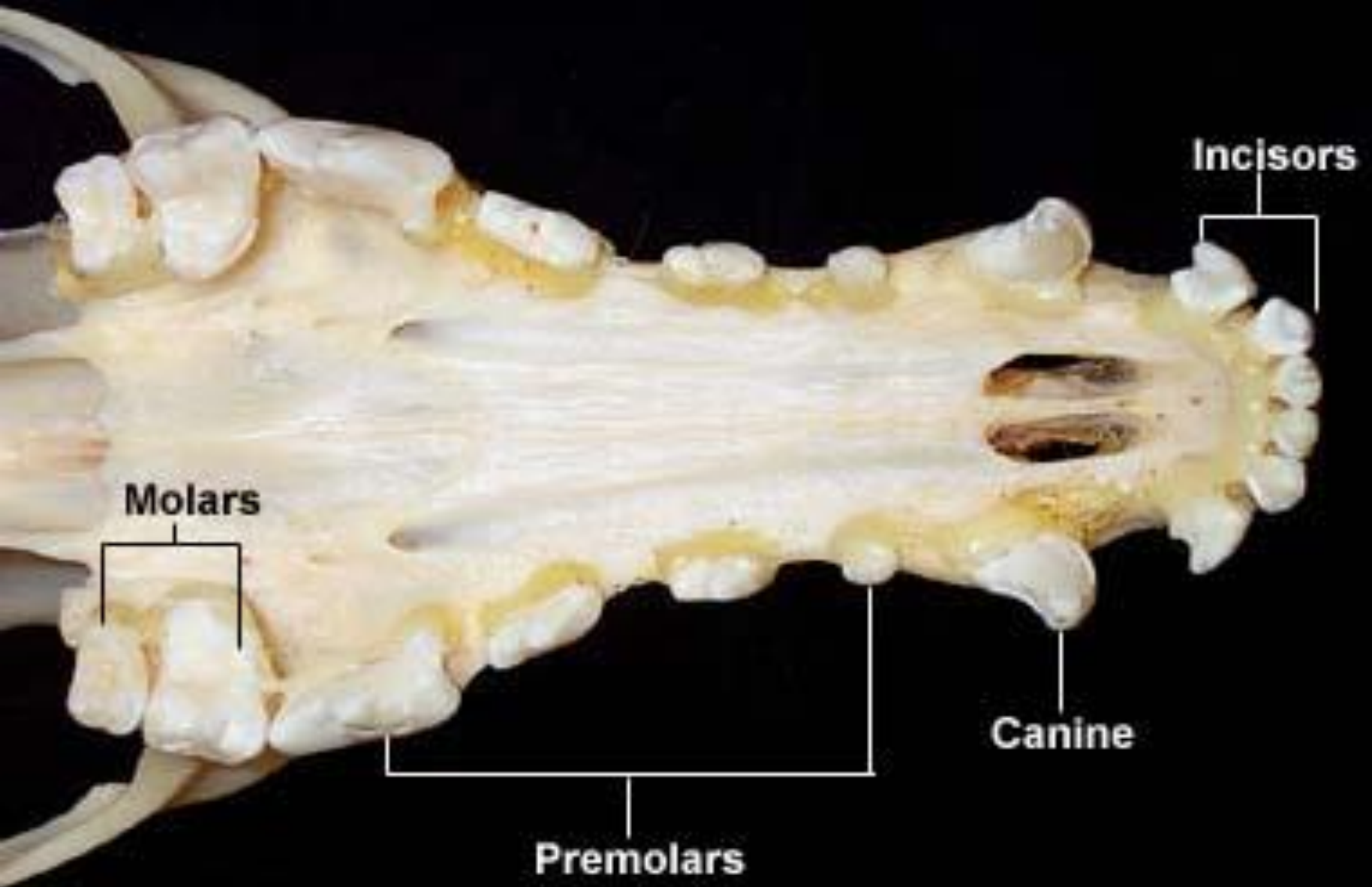


Dentition in Dog & Cat

(Dentition of Pets)



Characters of Teeth

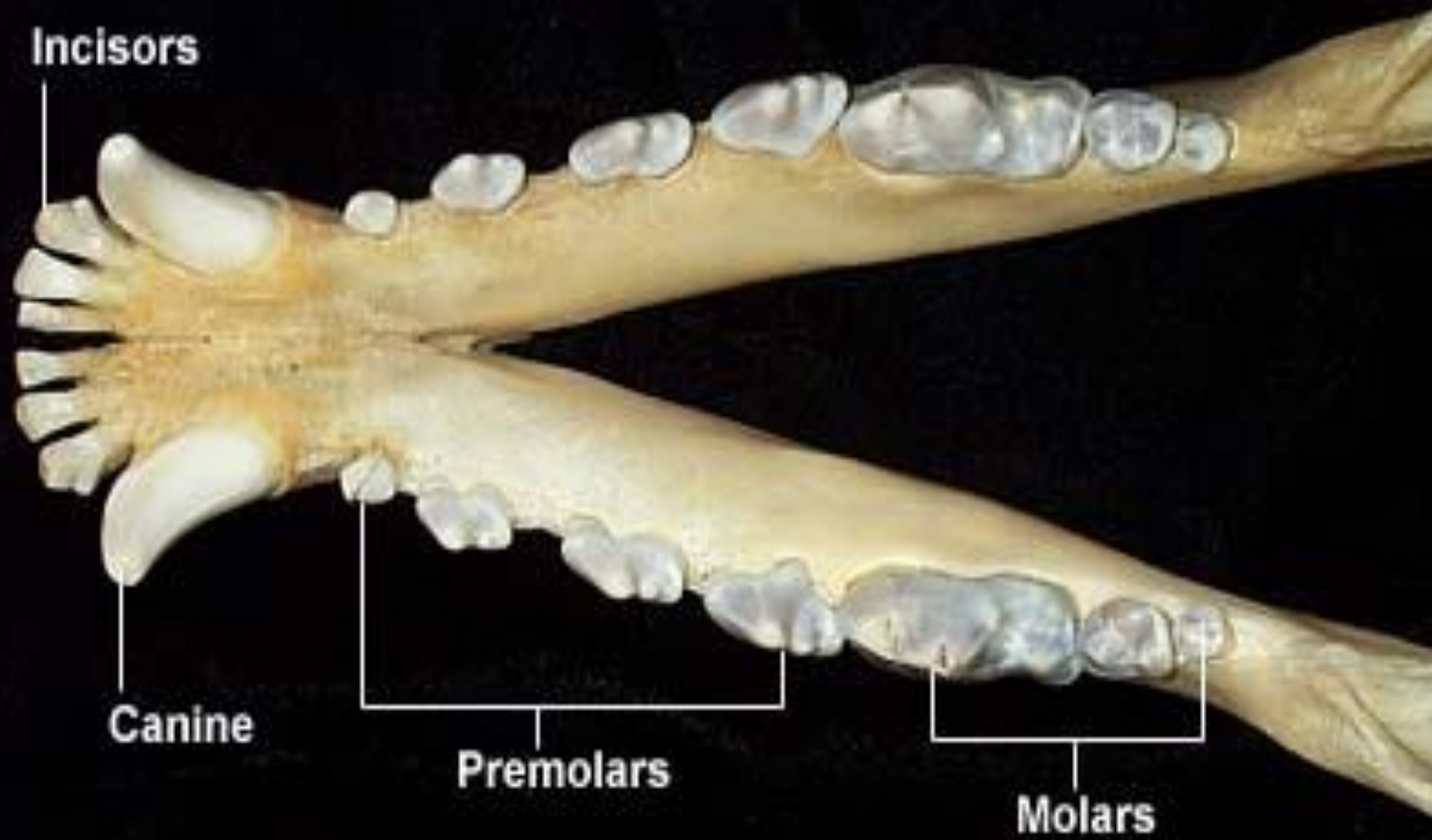


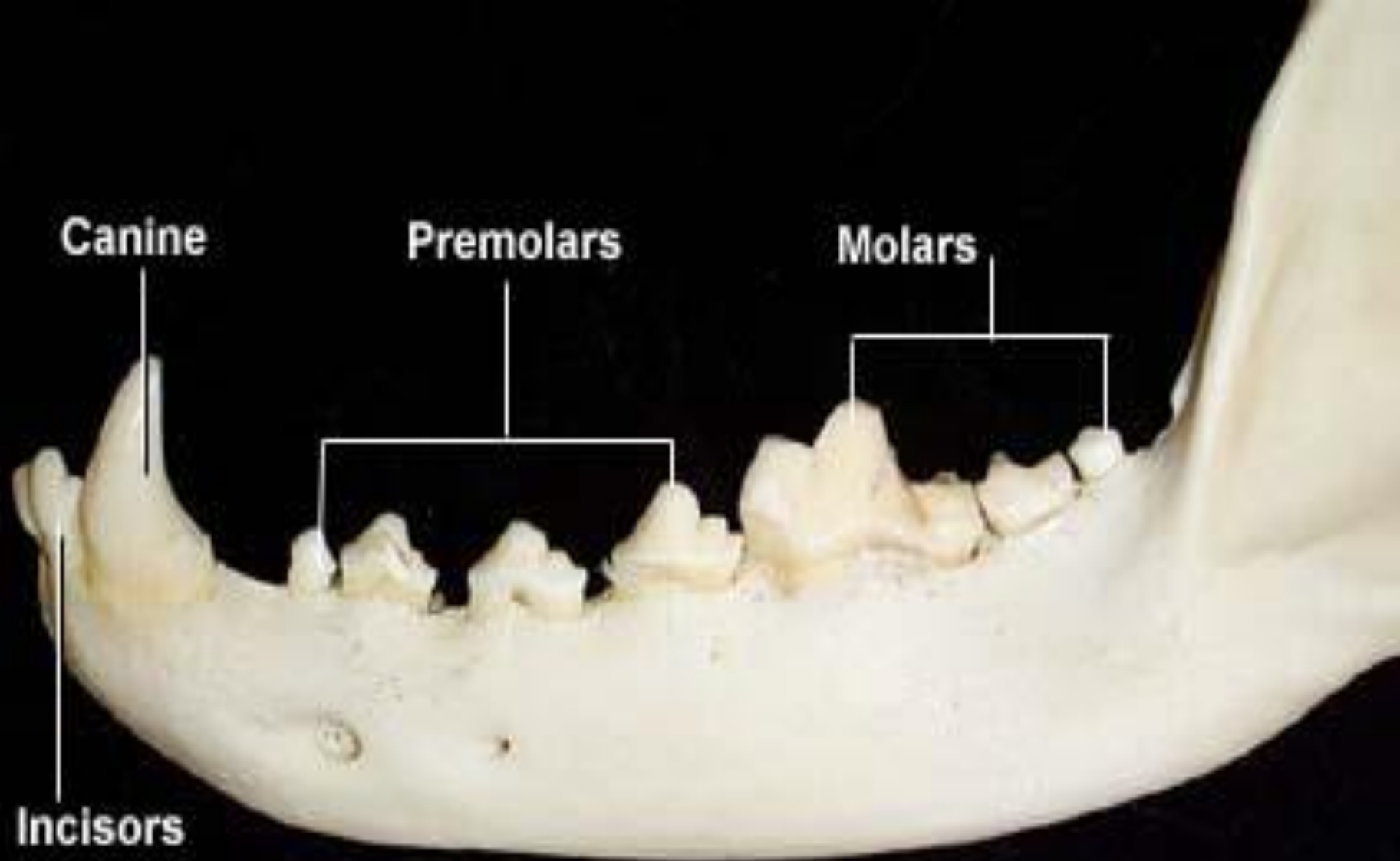
Incisors

Canine

Premolars

Molars



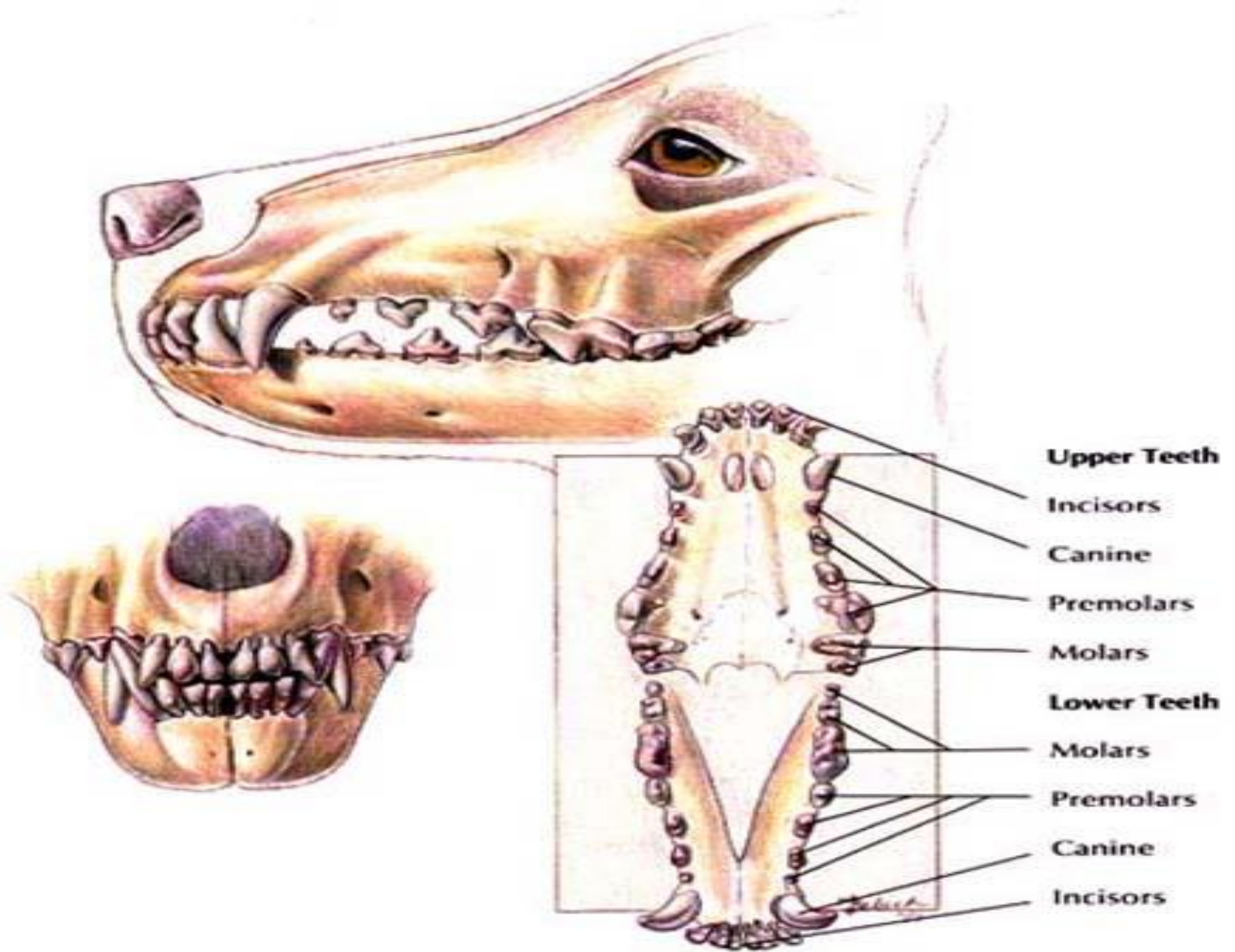


Canine

Premolars

Molars

Incisors

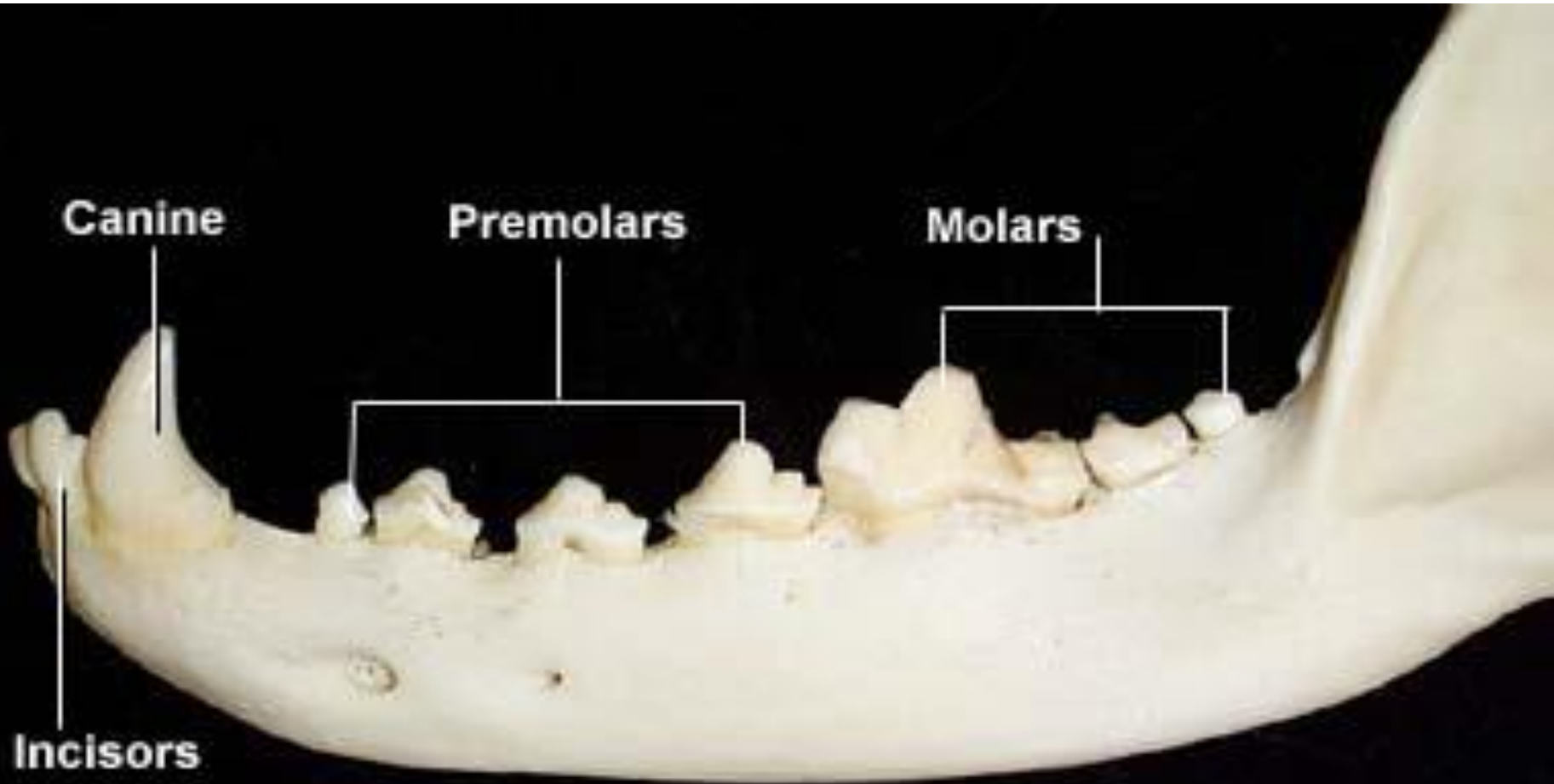


- Teeth of the pets are characterized by lotus shape (Cusps)
- There are 3 pairs of incisors
- Canines are one pair present temporary then replaced in permanent stage in male and female
- Premolars are 3 pairs

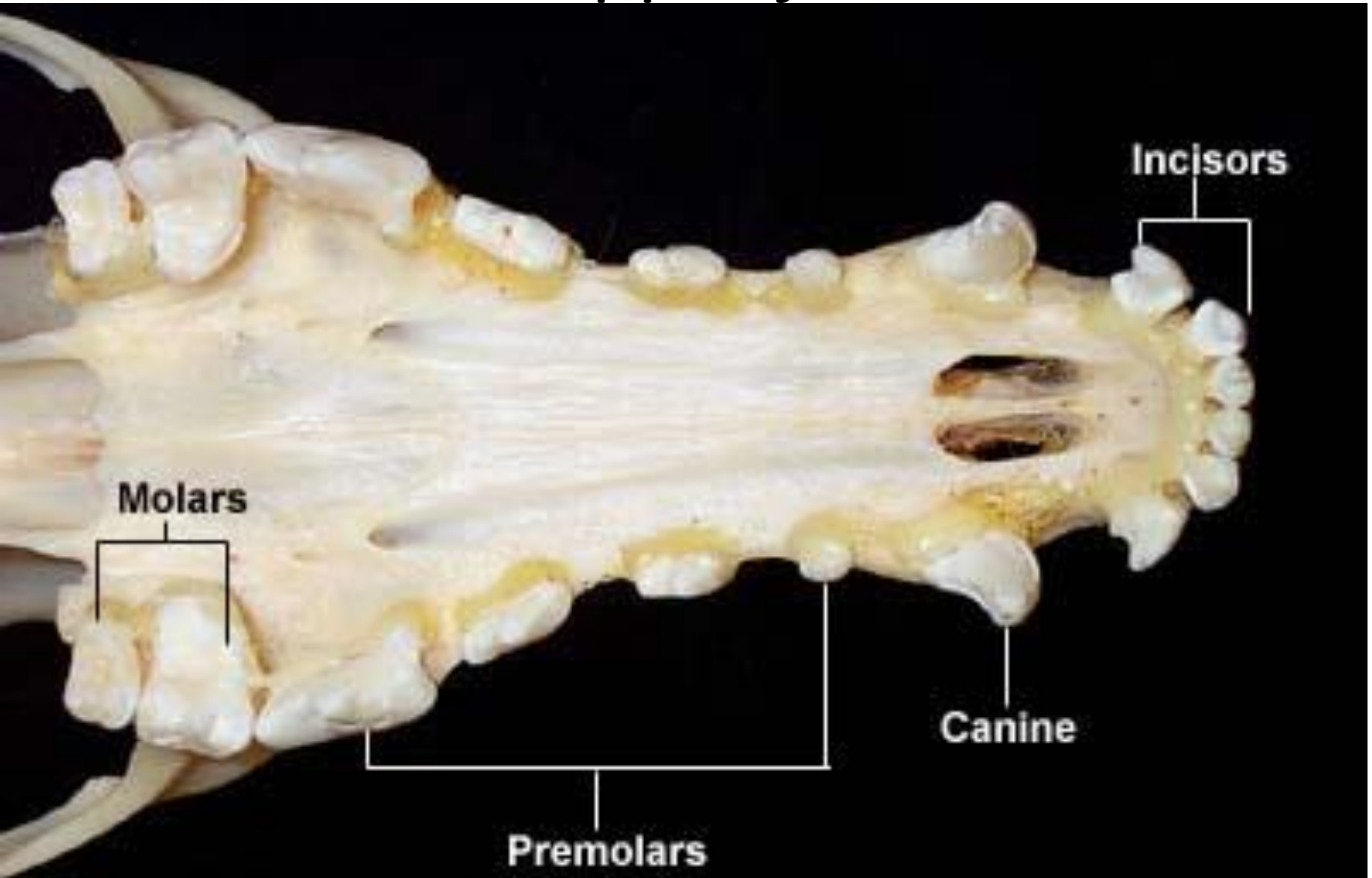
- *In permanent stage ...*

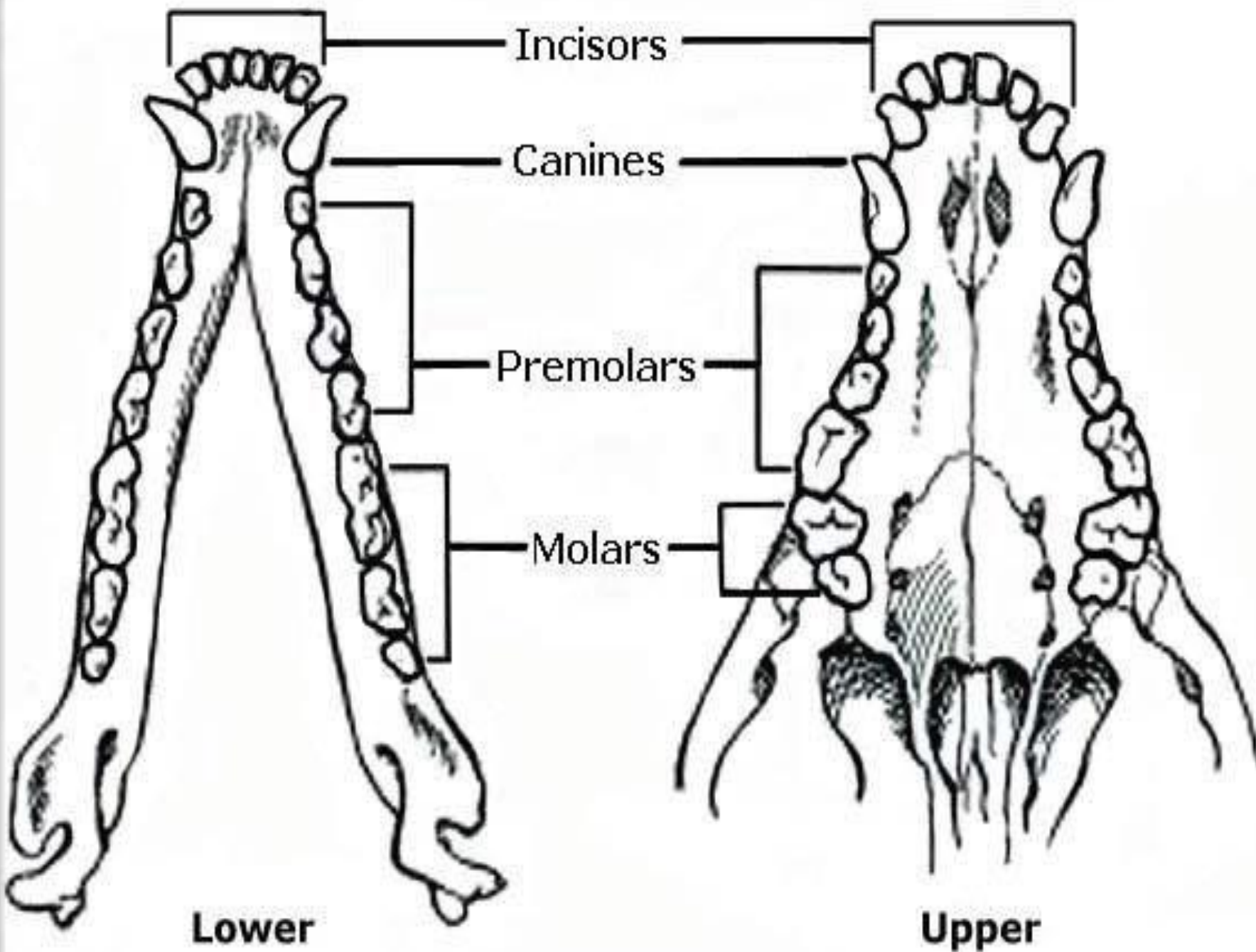
1. The premolars in upper and lower jaw are 4 pairs
2. The molars in upper jaw are 2 pairs while in lower are 3 pairs

Lower jaw



Upper jaw





Temporary dental formula

$$3 + 1 + 3 + 0$$

- T.D.F = $\times 2 = 28$ teeth

$$3 + 1 + 3 + 0$$

So the T.D.F in male and female = 28 teeth

Permanent dental formula



$$3 + 1 + 4 + 2$$

❖ *P.D.F = X 2 = 42 teeth*

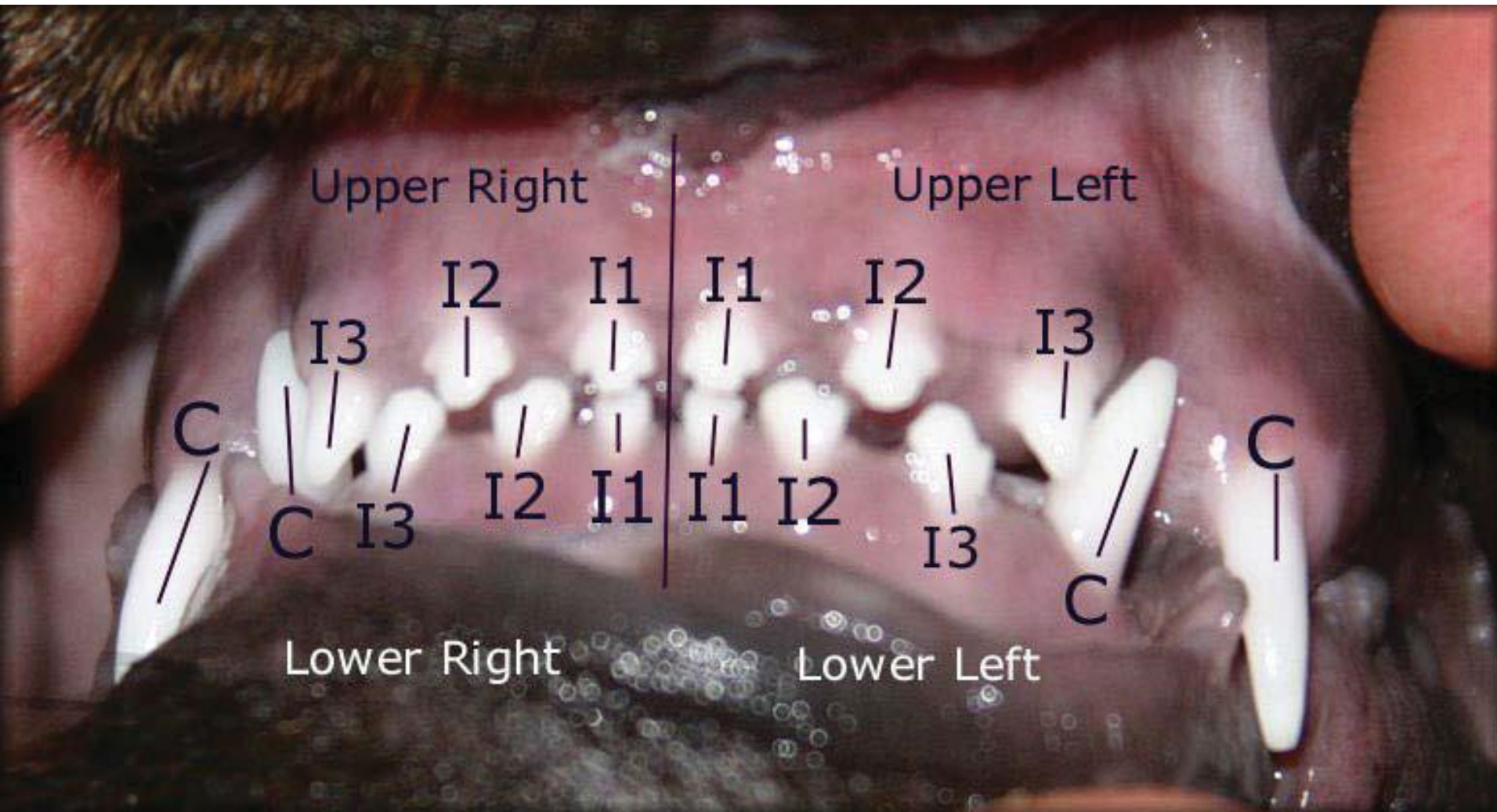
$$3 + 1 + 4 + 3$$

- *So the P.D.F in male & female = 42 teeth*




Temporary stage

- Puppies and kittens born without any teeth
- Canine  3- 4 wks
- Rest of teeth  4 – 5 wks

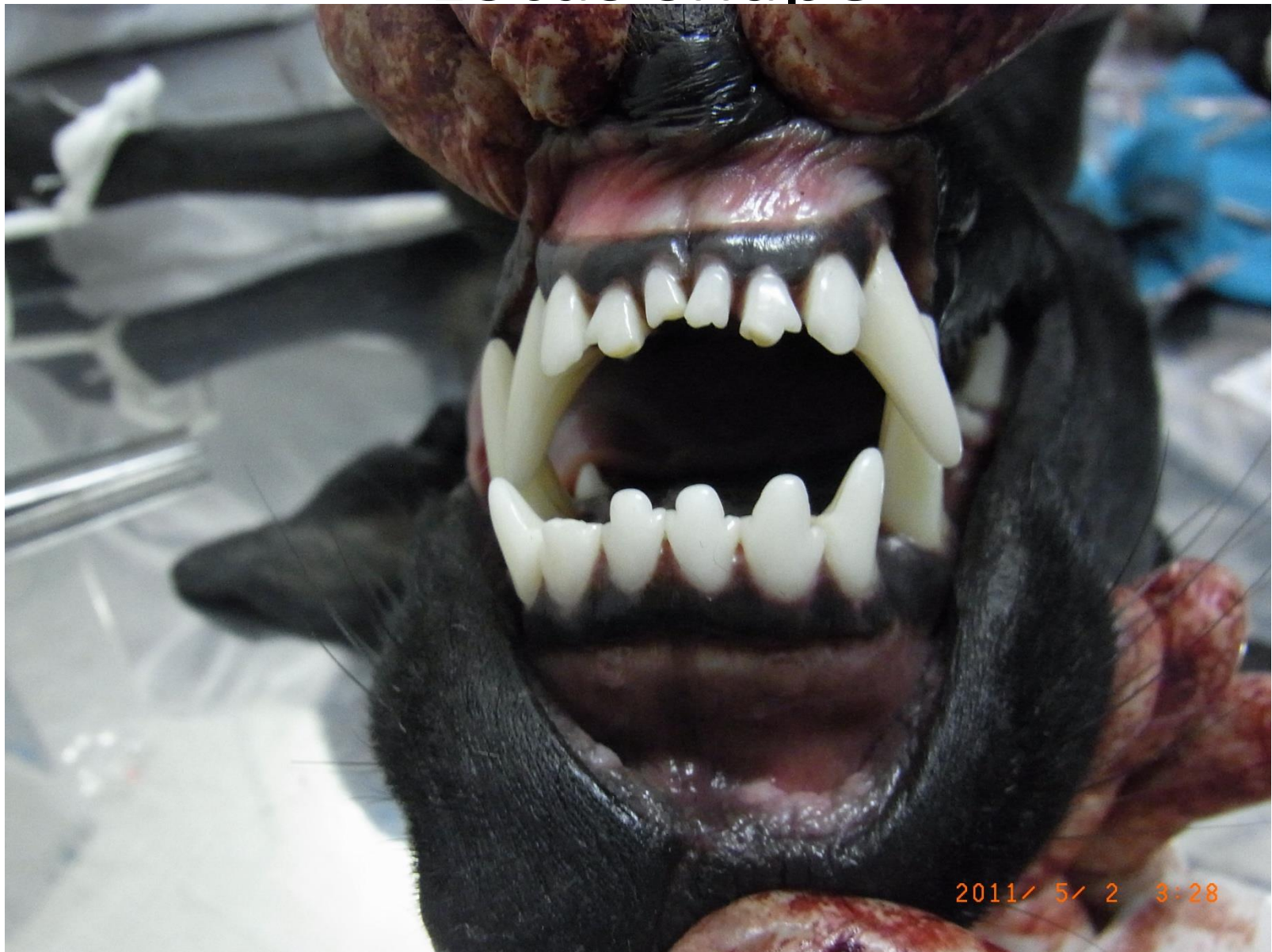Temporary stage



Permanent Stage

- First molar(lower jaw) and central, intermediate incisors and first & second premolars  4 months
- Second molar of lower and first molar of upper jaws , corner and canine and third & fourth premolar  5 – 6 months
- Second molar of upper jaw and third molar of lower jaw  6 – 8 months

Lotus shape



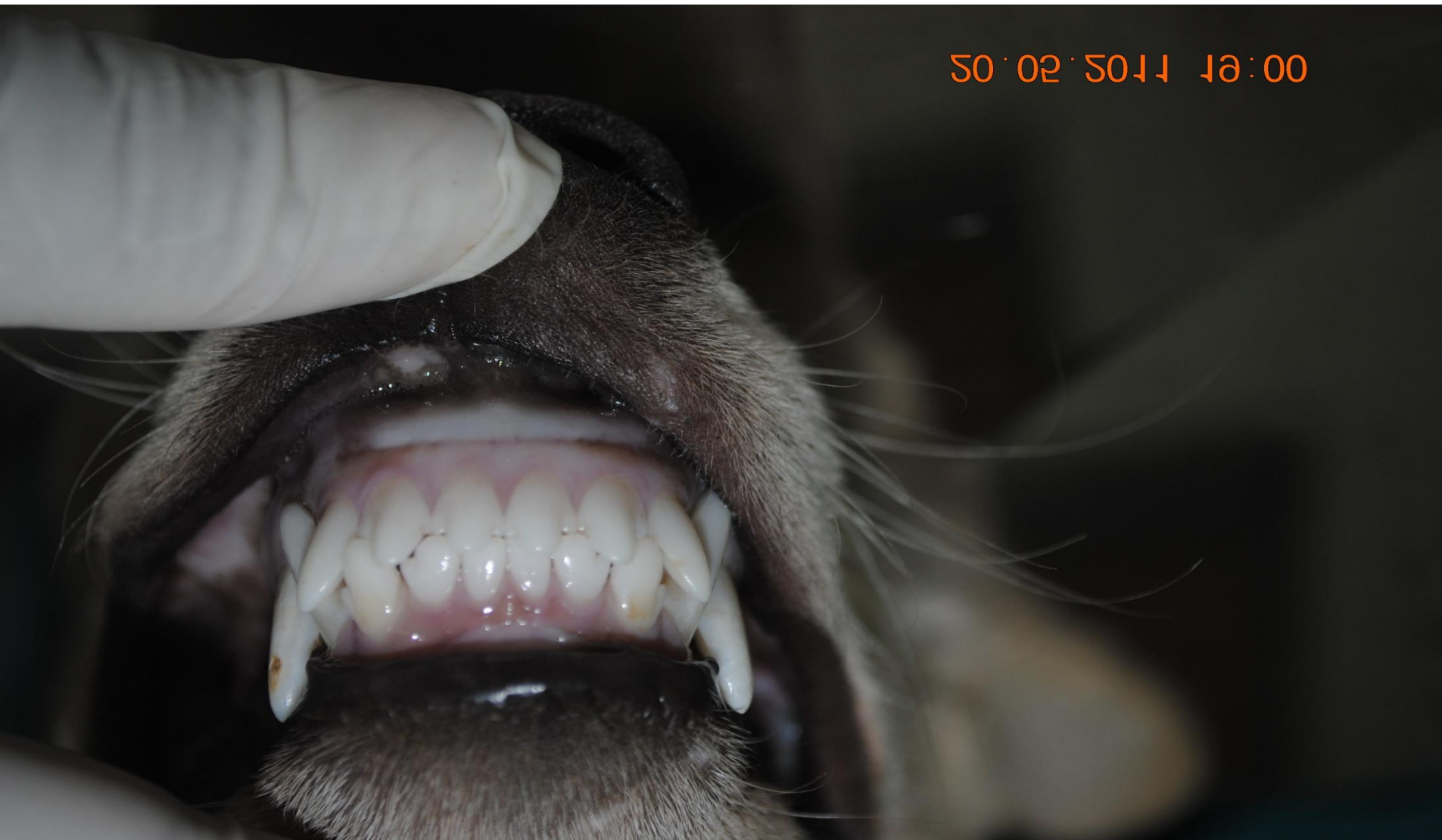- At 2 Yrs , the lotus disappear from lower central incisor then from lower intermediate one at 3 Yrs
- At 4 Yrs, the lotus disappear from upper central incisor then from upper intermediate one at 5 Yrs

1-2 Yrs

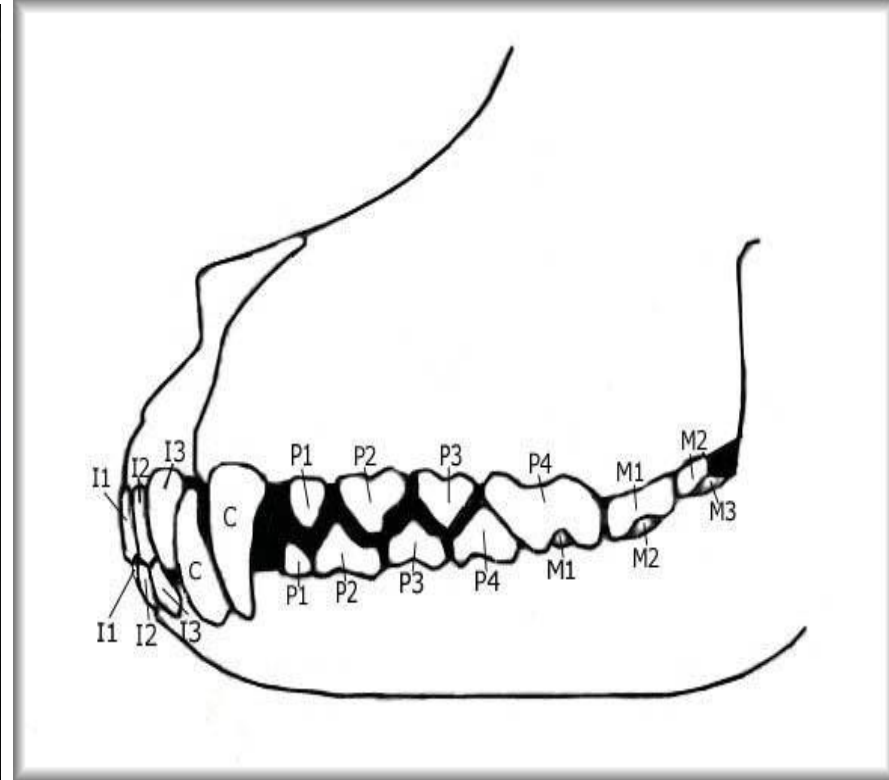
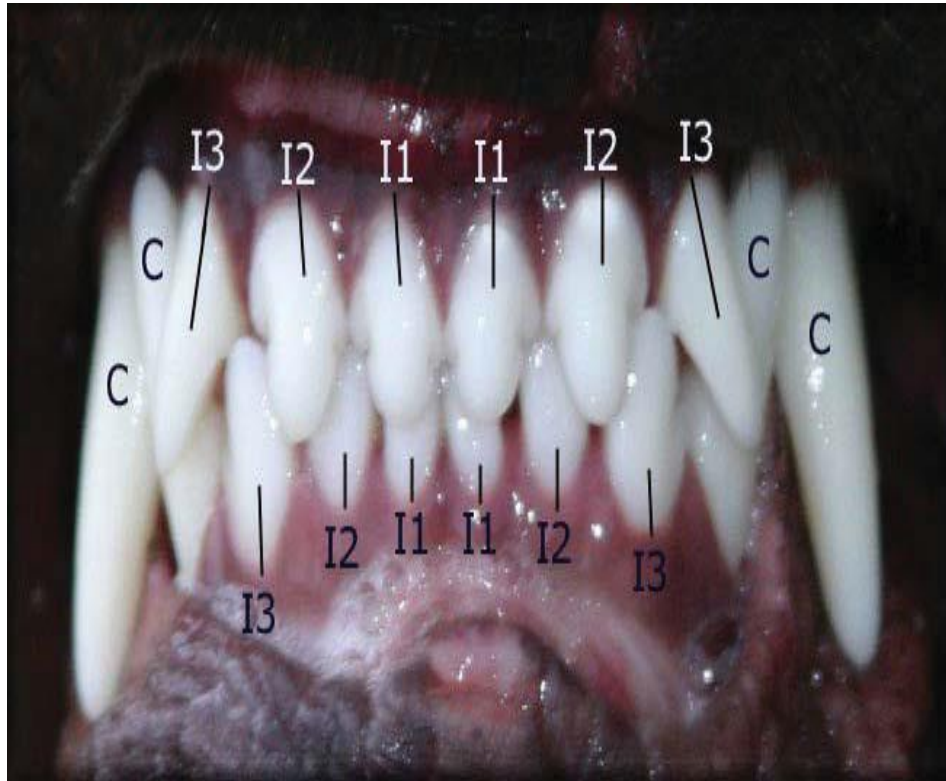


30.05.2011 15:35

3 years



The teeth should mesh properly.



Adult Teeth



Temporary stage

